The Laryngoscope
Lippincott Williams & Wilkins, Inc., Philadelphia
© 1999 The American Laryngological,
Rhinological and Otological Society, Inc.

A Safe, Alternative Technique for Inferior Turbinate Reduction

Michael Friedman, MD; Hasan Tanyeri, MD; Jessica Lim, MD; Roy Landsberg, MD; David Caldarelli, MD

Objective: **Submucous resection of the inferior turbinates is a conventional technique for reducing their size to achieve patent nasal airways in situations where an enlarged turbinate contributes to airway obstruction. Many techniques and complications have been described in the past. We describe a new inferior turbinate reduction technique performed with powered instrumentation and assess its success and complication rates.** ***Study Design:*** **A prospective study of 120 consecutive patients who underwent submucous resection of the inferior turbinates with a microdebrider.** ***Methods:*** **Patient questionnaires were used for subjective assessment of symptoms before and after the procedure. We graded each patient's inferior turbinates for size from I to III before and 6 weeks after surgery for objective analysis.** ***Results:*** **The common complications of standard submucous resection of inferior turbinates include excessive resection, postoperative bleeding, and crusting. The advantage of the microdebrider technique is the precise control of the amount of tissue and location of tissue that is removed on a submucosal plane. The complications encountered with this technique are limited to postoperative bleeding that occurred in 1.6% of patients. There was no crusting or excessive removal of tissue.** ***Conclusion:*** **The results show that submucous resection of inferior turbinates with a microdebrider is a safe method of achieving turbinate size reduction with minimal morbidity.** ***Key Words:*** **Submucous resection, inferior turbinate, turbinectomy, microdebrider.**

***Laryngoscope*, 109:1834–1837, 1999**

INTRODUCTION

The role of inferior turbinate pathology in the reduction of nasal airflow is well known.[1] Patients with hypertrophic turbinates or with vasomotor rhinitis often benefit from turbinate reduction when medical treatment fails.[2] Techniques of turbinate reduction include turbinectomy,[3] submucous turbinectomy,[4] inferior turbinoplasty,[5] cryotherapy,[6] submucous electrosurgery,[7] CO_2 laser turbinoplasty,[8] and others. No technique is perfect, and each is associated with known short-term and long-term complications such as bleeding and atrophic rhinitis.[9] The variety of surgical techniques available indicates the lack of consensus on the optimal technique.

Most of the techniques described involve treatment of submucous tissue with sacrifice of mucosa for access to the target area. Techniques such as partial or total inferior turbinectomy, cryosurgery, electrocautery, and laser all destroy the mucosa, thereby interfering with nasal physiology. Classic submucous resection of the inferior turbinates is a technique designed to preserve the mucosa, but it is, in fact, a misnomer because the resection includes some mucosa. The main goal of this type of surgery should be preservation of mucosal surfaces with reduction of the submucosal and bony tissue. Powered instrumentation used in a functional approach to inferior turbinates offers advantages over traditional techniques with regard to complications and mucosal preservation. We prospectively evaluated the effects of microdebrider inferior turbinectomies on alleviating nasal stuffiness as well as complications.

MATERIAL AND METHODS

Inclusion Criteria

A prospective study was performed involving adult patients with symptoms and signs of nasal obstruction and stuffiness related to enlarged turbinates who were treated from December 1997 to July 1998.

Criteria for inclusion consisted of enlarged inferior turbinates, with or without nasal septal deformity. Inferior turbinates were evaluated by anterior rhinoscopy and nasal endoscopy before and 6 weeks after surgery. We graded inferior turbinates from I to III. Grade I was defined as mild enlargement with no obvious obstruction. Grade III was complete occlusion of the nasal cavity. The turbinates in between were graded as II. All of the turbinates were graded by the first author (M.F.) before and after surgery. Grade II and grade III turbinates were included in the study.

Patients were required to complete questionnaires regarding nasal symptoms before the procedure and 6 weeks later. Nasal airway obstruction and stuffiness, crusting, and dryness in the nose were rated as mild, moderate, severe, or absent. Only patients with moderate or severe nasal airway obstruction and stuffiness and with no crusting and dryness in the nose were included in the study.

From Rush Presbyterian Saint Luke's Medical Center, Department of Otolaryngology Bronchoesophagology, Chicago, Illinois.

Editor's Note: This Manuscript was accepted for publication July 15, 1999.

Send Reprint Requests to Michael Friedman, MD, Department of Otolaryngology and Bronchoesophagology, 1653 West Congress Parkway, Chicago, IL 60612-3833, U.S.A.

Surgical Technique

Transpalatal sphenopalatine ganglion blocks were performed bilaterally with 1% lidocaine within 1/100,000 epinephrine. The inferior turbinates were injected with the same solution in a submucosal plane. An incision was made with a #15 blade in a vertical manner in the anterior aspect of the inferior turbinate (Fig. 1). A submucosal pocket was created with sharp dissection on the medial surface of the bony turbinate (Fig. 1). The straight microdebrider (4-mm tip with tricut blade) was applied through the incision. The bony turbinate and some of the submucosal tissue was debrided at 3000-cps oscillating mode in a ventrocaudal manner (Fig. 2). Debridement was performed with the blade positioned laterally from the submucosal plane. No lateral flap was developed. The 6000-cps forward mode was used at times when the bony turbinate was hard to debride. Particular attention was paid to preserve the mucosal flap. After encountering bleeding early in the series, we modified the procedure to include examination of the pocket with a 0° endoscope. Hemostasis was achieved under direct vision with suction electrocautery when necessary. The incision was not closed. The reduction in size of the inferior turbinate was easily recognized immediately after the procedure (Fig. 3). Sponge packing was used for 48 hours. Complications of bleeding, crusting, foul odor, mucosal tears, synechia, and nasolacrimal duct injury were recorded.

RESULTS

A total of 120 patients (78 male and 42 female patients) between the ages of 19 and 71 years with symptoms in the severe and moderate range and whose examination findings were consistent with grade II and III inferior turbinates met the inclusion criteria. A total of 112 patients underwent bilateral microdebrider inferior turbinectomy, and unilateral microdebrider inferior turbinectomies were performed on 8 patients. When necessary, patients underwent standard submucous resection of the septum. Minimum follow-up was 6 months, with a range of 6 to 12 months.

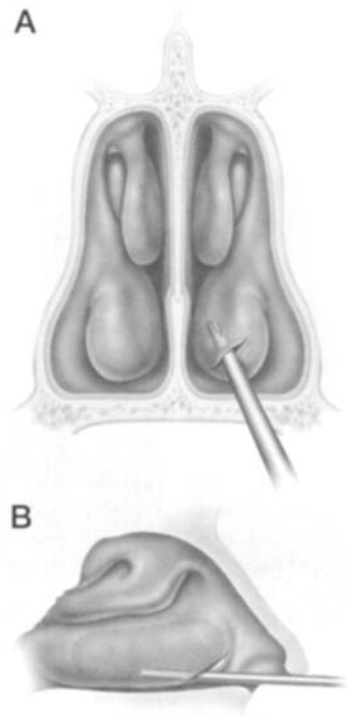

Fig. 2. **A.** Coronal section. The microdebrider is applied through this pocket. **B.** Sagittal section. The bony turbinate and the submucosal tissues are debrided with the blade facing laterally.

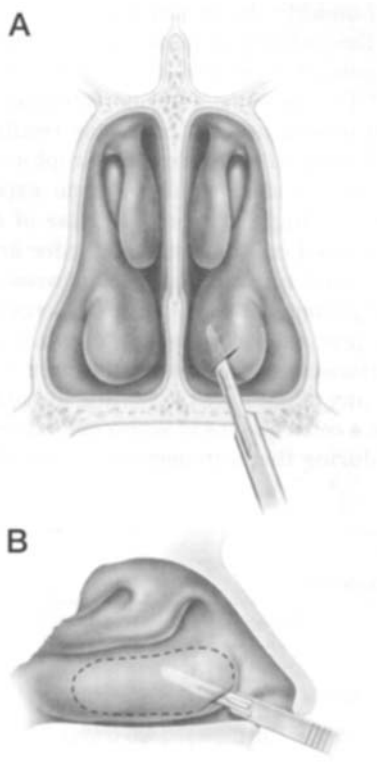

Fig. 1. **A.** Coronal section. Vertical incision is made at the caudal end of the inferior turbinate. **B.** Sagittal section. A submucosal pocket is created in anteroposterior plane over the bony turbinate.

Table I summarizes the subjective data gathered from the questionnaires. Symptoms of bilateral nasal obstruction and stuffiness were almost completely resolved. Eighty-three percent (n=100) of the patients suffered from severe and 17% (n=20) moderate nasal obstruction and stuffiness before the surgery. After the surgery, 25% (n=30) of the patients had mild nasal obstruction and stuffiness symptoms and 75% (n=90) had no nasal obstruction or stuffiness. None of the patients had crusting or dryness in the nose before surgery, and none developed these symptoms after surgery.

Table II summarizes objective data. A total of 232 inferior turbinates underwent microdebrider inferior turbinectomies. Eight patients underwent unilateral turbinectomies. There were 74 (32%) grade II and 158 (68%) grade III inferior turbinates before surgery. We observed 166 (72%) grade I and 66 (28%) grade II inferior turbinates after the surgery. All of the inferior turbinates exhibited a decrease in size after the procedure.

Postoperative bleeding that required a return to the operating room occurred in two patients (1.6%). In one case bleeding occurred after emergence from anesthesia. A branch of the sphenopalatine artery at the level of the choana was identified and bleeding was controlled with suction electrocautery. Bleeding from the pocket of the

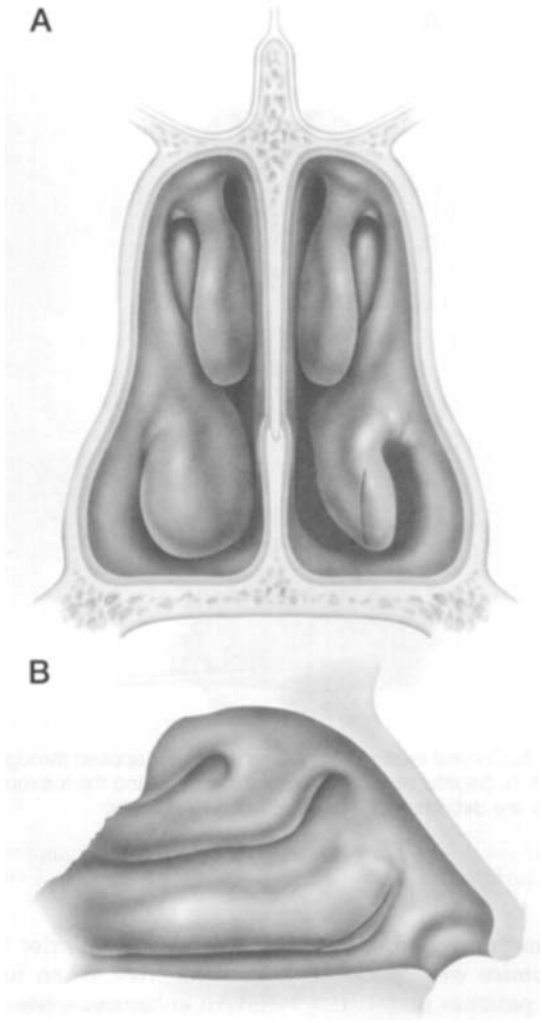

Fig. 3. **A.** Coronal section. The incision is not closed. **B.** Sagittal section. The decrease in the size of the turbinate is immediately recognized.

submucosal flap occurred 6 hours after surgery in another case and was controlled by electrocauterizing a bleeding vessel in the pocket. Neither patient suffered a significant change in vital signs, hemoglobin, or hematocrit levels. In the last 40 patients, the submucosal pocket was examined endoscopically and bleeding points were cauterized. There was no postoperative bleeding in this group. Mucosal tears were fairly common in 55% of the patients, but there was no loss of mucosa. We observed synechia in 5% of the patients. We did not observe any crusting, foul odor, or nasolacrimal duct injury complication (Table III).

DISCUSSION

Inferior turbinate surgery is advocated for relief of symptoms in patients with chronic nasal congestion.[2] Numerous reports substantiate the usefulness of inferior turbinate surgery.[3,10–13] Our patients had significant symptomatic relief after microdebrider turbinectomy, and our findings are consistent with other techniques reported in the literature. However, concomitant nasal septal surgery with the inferior turbinate surgery in some cases limits our ability to attribute the relief of nasal obstruction and stuffiness symptoms merely to the reduction in the size of the inferior turbinates. This is a fault in our study design. Nasal obstruction symptoms are often unilateral in patients with deviated nasal septum. This unilateral obstruction is corrected by septoplasty, but nasal stuffiness may persist in patients with inferior turbinate hypertrophy. Our study group comprised patients with nasal stuffiness and obstruction symptoms. The visual identification of turbinate reduction combined with the elimination of symptoms speaks for effective turbinate reduction.

The ideal turbinate surgery would be limited to the erectile submucosal tissue and to the bony turbinate. Reduction of bone creates more space, while surgery on submucosal tissue creates scarring that minimizes the engorgement of the inferior turbinates of patients with vasomotor rhinitis. Preservation of mucosa improves the chances for continued function of the inferior turbinates to warm and humidify the inspired air.

All of the techniques performed for turbinate reduction have potential complications that fall into several categories.[9] Partial or submucous resection of the turbinates is not precise and at times may result in excessive removal of tissue, with subsequent atrophic rhinitis. Most of the techniques also result in bone exposure, which complicates healing. Frequent sequelae of exposed bone include prolonged crusting with foul odor and sometimes bleeding. Inferior turbinate surgery is associated with an incidence of postoperative bleeding and crusting.[2,9] Tissue removal is precise and incremental with microdebrider inferior turbinectomy, and excessive removal was not a problem in any of our cases. Crusting did not occur at all. Foul odor is a consequence of scabbing and necrosis that is often seen during the postoperative course of inferior tur-

TABLE I.
Subjective Data Compiled From Questionnaires.

	Preoperative (n = 120)			Postoperative (n = 120)		
	n (%)			n (%)		
Symptom	Severe	Moderate	None	Severe	Mild	None
Bilateral nasal obstruction or stuffiness	100 (83%)	20 (17%)	0 (0%)	0 (0%)	30 (25%)	90 (75%)
Crusting	0 (0%)	0 (0%)	120 (100%)	0 (0%)	0 (0%)	120 (100%)
Dryness in the nose	0 (0%)	0 (0%)	120 (100%)	0 (0%)	0 (0%)	120 (100%)

TABLE II.
Objective Data.

	Preoperative (n = 232)		Postoperative (n = 232)	
Turbinate				
Grade	II	III	I	II
Quantity	74 (32%)	158 (68%)	166 (72%)	66 (28%)

TABLE III.
Complications (n = 120).

Bleeding	2 (1.6%)
Nasolacrimal duct injury	0
Mucosal tear	65 (55%)
Crusting	0
Foul odor	0
Synechia	7 (5%)

binectomies.[9,14] We did not observe any of these complications in our patients. We believe debulking of the turbinate while preserving the mucosa is the major advantage of this procedure. After encountering two patients with postoperative bleeding, we modified our technique and decreased the morbidity. Endoscopic examination of the turbinate pocket with suction electrocautery is routinely used to improve hemostasis on completion of the procedure. Postoperative bleeding is a complication associated with all turbinate reduction techniques.[9] Lippert and Werner[15] compared the CO_2 laser with Nd:YAG laser in treatment of hyperplastic inferior turbinates and mentioned postoperative bleeding rates up to 16% and marked crusting up to 52%. The microdebrider turbinectomy exhibits favorable complication rates compared with other techniques.

Patients with bony hypertrophy covered with a thin layer of mucosa are not good candidates for microdebrider turbinectomy. The thick, calcified bony turbinate makes the debridement difficult and might predispose the patient to mucosal tears. All of the mucosal tears were in the medial flap. We did not encounter any lateral mucosal flap tear. We believe preservation of some of the bony turbinate prevents this complication.

Mucosal tears were fairly common (55%), but very few of them persisted as synechia to the septum (5%). Delicate septal surgery without any mucosal damage also prevents this complication. The incidence of tears decreased significantly during the course of this study owing to the learning curve of a new procedure. When tears do occur, no treatment is needed.

The study demonstrates a technique that improves symptoms and reduces complications in patients with inferior turbinate hypertrophy. However, the relative short follow-up is insufficient to make definitive statements about the long-term outcome.

CONCLUSION

Microdebrider submucous resection of inferior turbinates is a safe method of achieving turbinate size reduction with acceptable morbidity in patients with nasal airway obstruction secondary to turbinate disease. Bleeding is a rare complication. Preservation of mucosa leads to early healing and absence of crusting and exposed bone. The microdebrider technique lends itself to precise tissue removal with satisfactory reduction of tissues.

BIBLIOGRAPHY

1. Proctor DF, Bridger GP. Flow and nasal resistance. *Ann Otol* 1970;79:482–488.
2. Kimmelman CP, Gamal HA. Vasomotor rhinitis. *Otolaryngol Clin North Am* 1986;65:65–71.
3. Martinez SA, Nissen AJ, Stock CR, Tesmer T. Nasal turbinate resection for relief of nasal obstruction. *Laryngoscope* 1983;93:871–875.
4. Fanous N. Anterior turbinectomy. A new surgical approach to turbinate hypertrophy: a review of 220 cases. *Arch Otolaryngol Head Neck Surg* 1986;112:850–852.
5. Mabry RL. Inferior turbinoplasty: patient selection. Technique, long term consequences. *Otolaryngol Head Neck Surg* 1987;98:68–66.
6. Moore JR, Bicknell PG. A comparison of cryosurgery and submucous diathermy in vasomotor rhinitis. *J Laryngol Otol* 1980;94:1411–1413.
7. Talaat M, El Sabawy E, Baky FA, Raheem AA. Submucous diathermy of the inferior turbinates in chronic hypertrophic rhinitis. *J Laryngol Otol* 1987;101:452–460.
8. Lippert BM, Werner JA. Comparison of carbon dioxide and neodymium:yttrium-aluminum-garnet lasers in surgery of the inferior turbinate. *Ann Otol Rhinol Laryngol* 1997;106: 1036–1042.
9. Dawes PJ. The early complications of inferior turbinectomy. *J Laryngol Otol* 1987;101:1136–1139.
10. Pollock RA, Rohrich RJ. Inferior turbinate surgery: an adjunct to successful treatment of nasal obstruction in 408 patients. *Plast Reconstr Surg* 1984;74:227–236.
11. Ophir D, Shapira A, Marshak G. Total inferior turbinectomy for nasal airway obstruction. *Arch Otolaryngol* 1985;111:93–95.
12. Salam MA, Wengraf C. Concho-antropexy or total inferior turbinectomy for hypertrophy of the inferior turbinates? A prospective randomized study. *J Laryngol Otol* 1993;107: 1125–1128.
13. Williams HO, Fisher EW, Golding-Wood DG. Two-stage turbinectomy: sequestration of the inferior turbinate following submucosal diathermy. *J Laryngol Otol* 1991;105:14–16.
14. Elwany S, Harrison R. Inferior turbinectomy: comparison of four techniques. *J Laryngol Otol* 1990;104:206–209.
15. Lippert BM, Werner JA. CO_2 laser surgery of hypertrophied inferior turbinates. *Rhinology* 1997;35:33–36.