

---

How I Do It

A Targeted Problem and Its Solution

---

# Inferior Turbinate Flap for Repair of Nasal Septal Perforation

---

Michael Friedman, MD; Hani Ibrahim, MD; Vidyasagar Ramakrishnan, MD, MBBS, MS

## INTRODUCTION

Many surgical techniques are available for surgical repair of nasal septal perforations. The variety of techniques is evidence that no single technique is recognized as being uniformly reliable in closing all perforations. In fact, most perforations remain unclosed because available closure techniques are technically difficult and require training and experience to master. Many authors have described high success rates with their techniques, but these results are not reproducible by all surgeons.<sup>1,2</sup> We have found success using the inferior turbinate as a composite flap as an option that may be helpful in selected cases. It is not to be presented as a replacement to currently accepted standard techniques using advancement flaps, but certainly may be an option in caudal septal perforations when advancement techniques are more difficult.

## MATERIALS AND METHODS

### *Surgical Technique*

This technique is limited to repair of septal perforations of moderate size (1.5–3.0 cm in diameter). Although the location of the perforation is not a contraindication, caudal perforations are easier to repair and the flap reaches all the way to the columella. The flap depends on a normal or large inferior turbinate. Previously operated turbinates or patients with atrophic rhinitis are not candidates for this procedure. Although we have used only unilateral flaps, theoretically, bilateral flaps could be used as well. All tissues are infiltrated with a solution with epinephrine (1:100,000) for homeostasis. The perforation is rimmed with a No.

12 blade to obtain fresh margins (Fig. 1). The turbinate is harvested with the use of 0° and 30° endoscopes. The flap is pedicled anteriorly, and the inferior half of the turbinate is the donor tissue. The flap is outlined under endoscopic control, and the superior medial mucosa incision is made with a knife from the posterior margin to the pedicle (anteriorly) (Fig. 2). The flap is then completed with a scissor, going through the turbinate bone and lateral mucosa to a point just cephalad to the pedicle and extending to the posterior border (Fig. 3). The flap includes mucosa, submucosa, and a variable amount of bone depending on the size of the turbinate. Any exposed bone from the flap or donor site is removed. The flap is rotated anteriorly and adjusted to fill the perforation. The distal portion of the flap is opened to create a mucosal surface on one side and soft tissue (submucosa of the turbinate) on the other side (Fig. 4). It is sutured with 4-0 plain catgut to surrounding tissue (Fig. 5). The contralateral side is left open for closure by secondary intention. The incision site and the remaining upper half of the turbinate is visualized with an endoscope to control any bleeding points with cautery. The donor site is left open and allowed to heal, which is frequently the case after partial turbinectomy. Three weeks later, the pedicle is taken down in an outpatient procedure with the use of local anesthetic. Bipolar cautery is used for hemostasis. The pedicle is transected (Fig. 6). The excess pedicle is discarded. At 3 weeks after surgery, the contralateral side of the flap has usually re-epithelialized. The patients are instructed to keep the sides moist with nasal saline spray during the 3-week period.

### *Results and Complications*

Follow-up has ranged from 18 months to 3 years. Ten patients have been treated with this technique between 1998 and 2001. Seven have had closure of their perforations. These perforations varied in vertical height from 1 to 2 cm. However, one of these seven patients had a bulky flap that resulted in nasal obstruction. Subsequent radiofrequency reduction of the bulky flap at 6 months after the procedure resulted in a re-perforation. Two other patients had incomplete closure with a small residual perforation. One patient, who had previous partial resection of the inferior turbinate, had flap necrosis with complete failure of the repair. No other complications were noted. As would be expected, all of the patients complained of unilateral nasal airway obstruction for the 3 weeks between stages of the perforation.

---

Presented at the Middle Section Meeting of The Triological Society, Oklahoma City, OK, January 18–20, 2002.

From the Department of Otolaryngology and Bronchoesophagology, Rush–Presbyterian–St. Luke's Medical Center, and the Division of Otolaryngology, Advocate Illinois Masonic Medical Center, Chicago, Illinois, U.S.A.

Editor's Note: This Manuscript was accepted for publication May 19, 2003.

Send Correspondence to Michael Friedman, MD, 30 North Michigan, Suite 1107, Chicago, IL 60602, U.S.A. E-mail: Khender213@aol.com

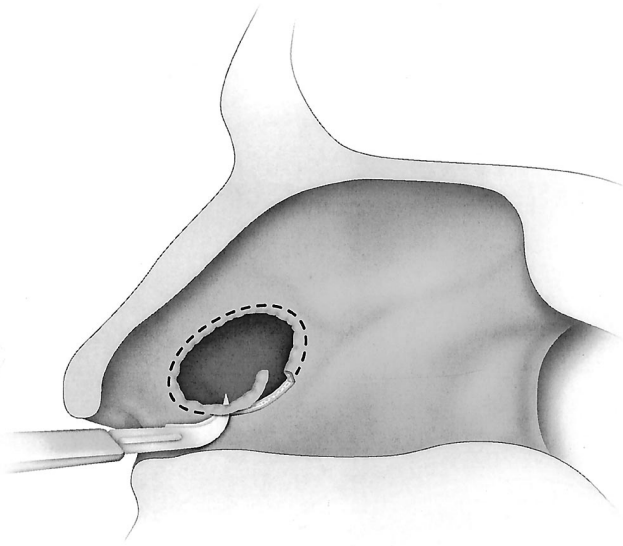


Fig. 1. The septal perforation is rimmed using a No. 12 blade.

## DISCUSSION

Nasal septal perforations differ widely in cause or origin, size, location, and symptomology. Symptomology is essential in determining whether a perforation should be repaired. Most perforations go unnoticed by the patient and therefore need not be repaired. However, some perforations cause significant symptoms of bleeding, crusting, and whistling.

Although iatrogenic perforations secondary to nasal septal surgery are the most common cause, trauma, cauterization, cocaine use, vasculitis, and idiopathic and other causes have all been implicated. The neighboring cartilage, mucosa, and submucosa may be normal or vari-

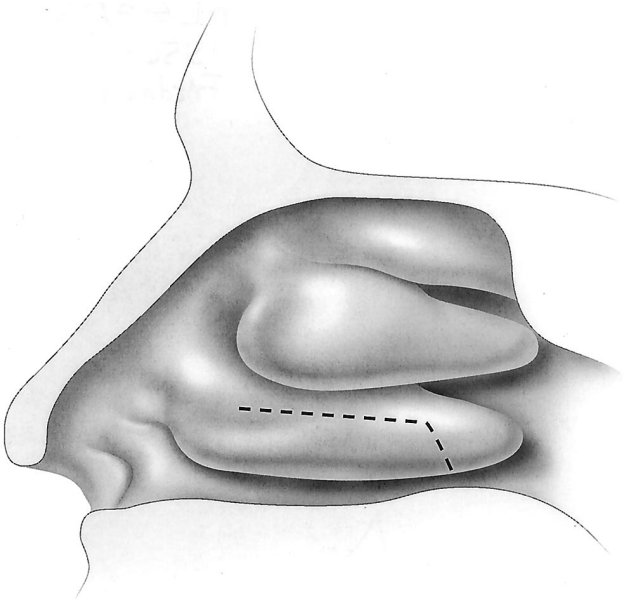


Fig. 2. The intended incision site. The anterior attachment of the turbinate is left intact.

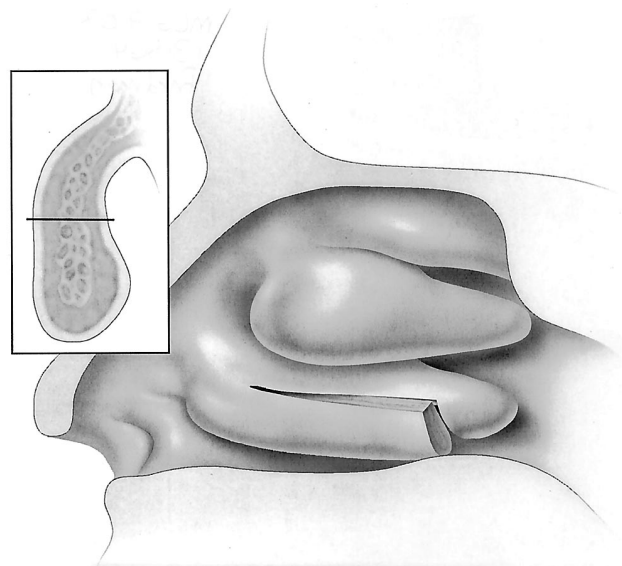


Fig. 3. A through-and-through cut is made through the inferior turbinate, leaving one-third to half of the superior portion of the turbinate intact, depending on the size of the turbinate.

ably diseased depending on the cause of the perforation. The decision to repair a perforation and what tissues to use certainly are influenced by the health of the local tissues that will be used in the repair. Clearly, the ideal repair would resurface the septum with respiratory mucosa of nasal origin.

Size is a crucial factor as well in determining the wisdom of proceeding with surgical repair, in determining the type of repair, and in predicting success of repair. Small perforations are generally treated with local advancement flaps from the remaining septum with an underlying connecting tissue autograft.<sup>3</sup> Huge, near-total perforations cannot be repaired with local tissue. Techniques using temporal parietal-fascia flaps and other regional flaps have been described for repair of these large perforations. Kridel et al.<sup>4</sup> popularized an external septorhinoplasty approach. Many two-stage procedures also have been described for larger perforations.<sup>5</sup> Success rates range from 40% to 95% in the reported series.<sup>5</sup> However, most otolaryngologists have not adopted the more complex repairs and probably experience poor overall success rates with intranasal procedures unless they have been specifically trained and are willing to spend the time and effort to perform meticulous flap elevation. The technique described by Fairbanks<sup>3</sup> is the most commonly used and successful technique for moderate-size perforations. The inferior turbinate flap has been used for perforations up to 2 cm in height but has not been tested on larger perforations.

The location of the perforation is a key element in the decision to perform or not to perform repair and in the type of repair to use. Posterior perforations are harder to repair with advancement flaps but are less likely to cause symptoms. Caudal perforations are also more difficult to repair with advancement flaps. The inferior turbinate flap is ideal for caudal perforations but equally suitable for perforations of the mid septum.

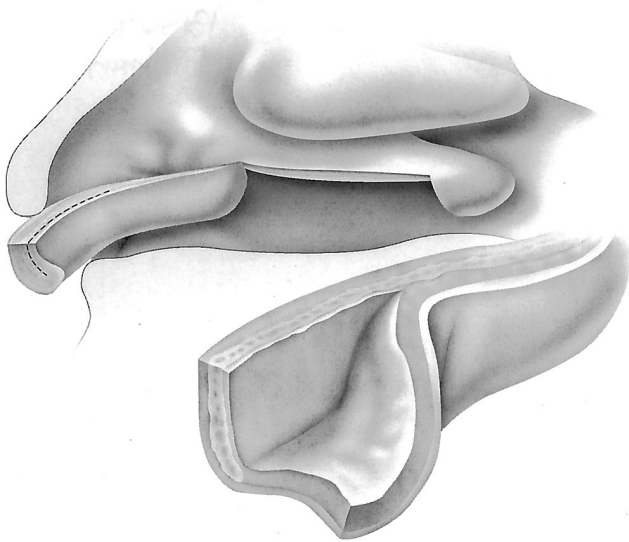


Fig. 4. The flap is retracted anteriorly, and the free edge is unfolded to slightly exceed the size of the perforation.

The key advantages of the inferior turbinate flap are abundant vascularity, wide arc of rotation, combined skeletal and epithelial support, and ease of development and insertion. The flap depends on an inferior turbinate of normal or large size. Another important advantage is that it uses respiratory tract mucosa, which allows the repaired septum to achieve physiological normalcy. Other methods that use skin grafts or buccal mucosa grafts may be effective in closing the perforation but leave the patient with a dry nose that continues to crust because skin normally sheds and normal respiratory tract mucosa is not present.<sup>6</sup> The major disadvantage is the requirement for a second-stage procedure to release the pedicle. The abun-

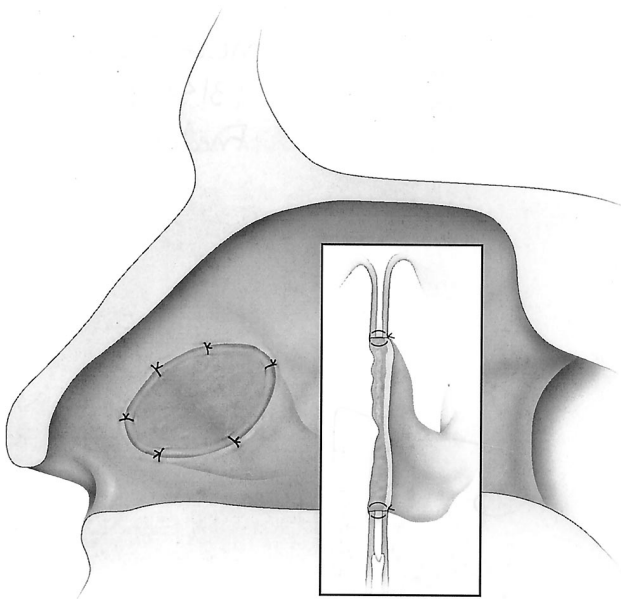


Fig. 5. The flap is sutured in place using plain 4-0 catgut.

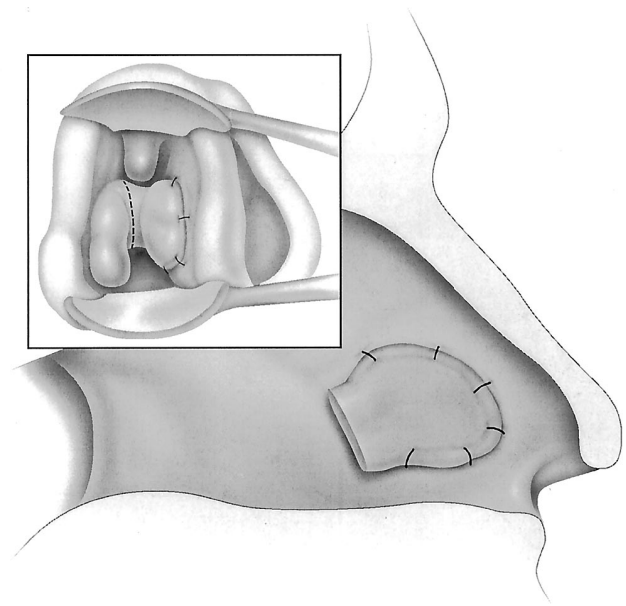


Fig. 6. The site of pedicle transection (3 weeks after surgery) is denoted by the dotted line.

dance of tissue that makes it a reliable flap is also a disadvantage because the flap may have enough bulk to cause partial obstruction of the airway. Assessment of the appropriate flap volume is important in preventing this complication.

Another disadvantage is that one surface is not epithelialized and must heal by secondary ingrowth of epithelium. We have tried lining the contralateral size with Alloderm with no obvious advantage in decreasing healing time or crusting. However, after 3 weeks, most flaps are re-epithelialized. Perhaps the use of daily applications of antibiotic ointment or the use of plastic septal splints may be helpful to further reduce the crusting during the healing process.

Weerda<sup>7</sup> mentioned the use of a turbinate flap in *Reconstructive Facial Plastic Surgery: A Problem-Solving Manual*. He described a technique that resected the entire turbinate. However, he provided no details or results of his technique. The technique we have used and describe is based on preservation of turbinate function by using only half of the turbinate. In addition to preserving turbinate function, use of half of the turbinate minimizes excess flap bulk that would obstruct the airway.

All the techniques described for surgical repair of the septal perforation are valuable in selected situations by the right surgeon. Familiarity with this new technique allows for more options to correct a difficult problem. Many patients who seek perforation repair have already failed local advancement flaps from the septum; therefore, flaps from other areas are needed. Other patients have had extensive previous septal surgery with removal of cartilage and also are not candidates for local advancement flaps. The inferior turbinate provides easily accessible tissue that, in many cases, has not been previously traumatized.

## CONCLUSION

The inferior turbinate flap for repair of nasal septal perforations of moderate size is a relatively simple technique that offers a success rate comparable to or better than most techniques. It offers a valuable source of respiratory tract mucosa that may be healthy when septal mucosa had been previously damaged. Any endoscopic surgeon can master the technique. It provides one more alternate solution to a difficult problem.

## BIBLIOGRAPHY

1. Vuyk HD, Versluis RJ. The inferior turbinate flap for closure of septal perforations. *Clin Otolaryngol Allied Sci* 1988;13:53–57.
2. Masing H, Gammert C, Jaumann MP. Our concept concerning treatment of septal perforations. *Laryngol Rhinol Otol* 1980;59:50–56.
3. Fairbanks DN. Closure of nasal septal perforations. *Arch Otolaryngol Head Neck Surg* 1986;112:1283–1285.
4. Kridel RW, Appling WD, Wright WK. Septal perforation closure utilizing the external septorhinoplasty approach. *Arch Otolaryngol Head Neck Surg* 1986;112:168–172.
5. Romo T. A graduated approach to the repair of nasal septal perforations. *Plast Reconstr Surg* 1999;103:66–75.
6. Kridel RW. Septal perforation repair. *Otolaryngol Clin North Am* 1999;32:695–724.
7. Weerda H. *Reconstructive Facial Plastic Surgery: A Problem-Solving Manual*. New York: Thieme, 2001.